



Summary Feedback

(Combined feedback broadcasted at multiple times this week)

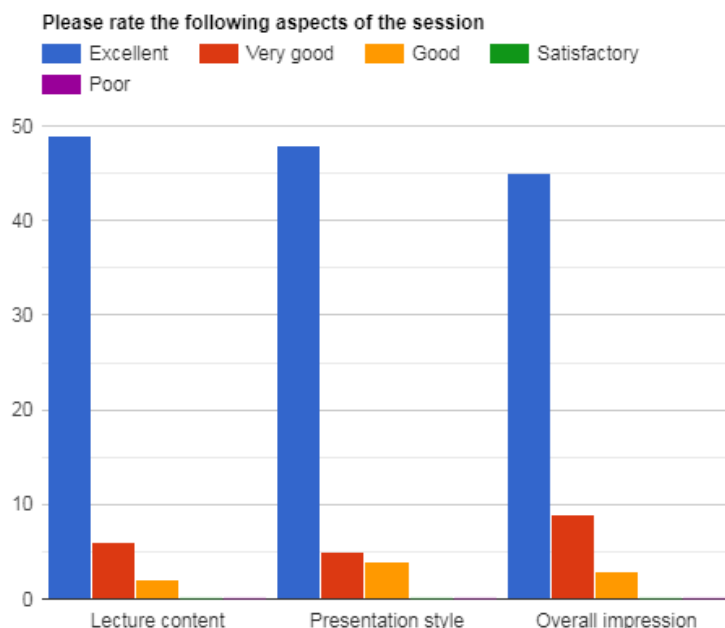
PRE-RECORDED: Basildon FRCR 2B 'A to Zee' Course 2020

Session 3/40

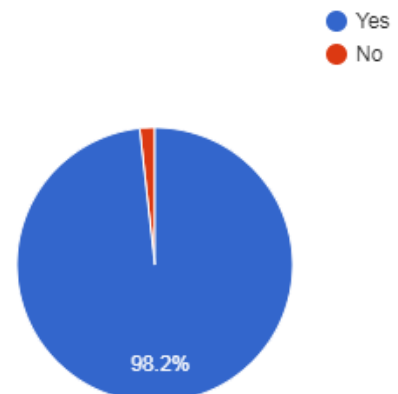
Chest & Cardiac Imaging For FRCR - Part 1
(18th and 19th May 2024)
Lecturer: Alexia Farrugia

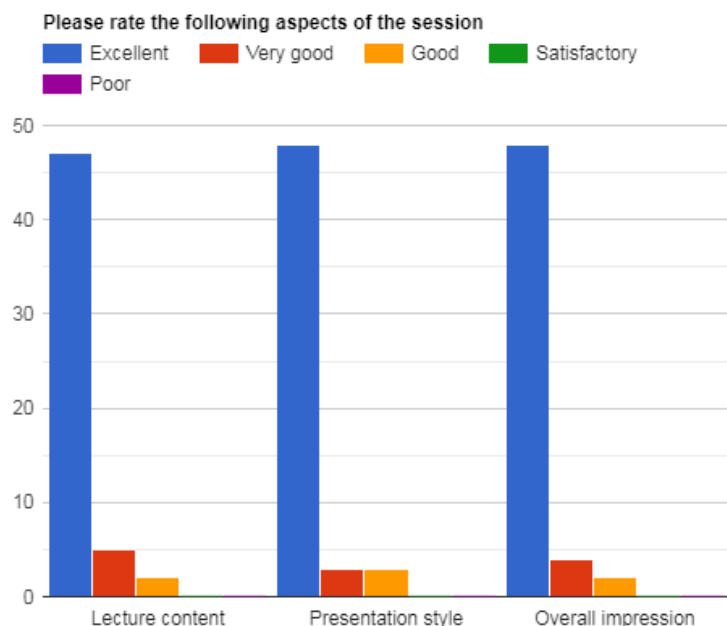
Summary Points:

- Total Attendees: 396 from 36 Countries (Algeria, Bahrain, Bangladesh, Dominica, Egypt, Germany, Ghana, Hong Kong, India, Indonesia, Iran, Iraq, Jordan, Kenya, Kuwait, Libya, Malaysia, Malta, Nepal, Nigeria, Oman, Pakistan, Poland, Qatar, Saudi Arabia, Singapore, South Africa, Sri Lanka, Sudan, Swaziland, Türkiye, UAE, UK, Ukraine, Yemen, Zimbabwe).
- Total duration: 2 hours (each session broadcasted thrice during the week)
- Total feedback received from 124 participants, from three different broadcasts

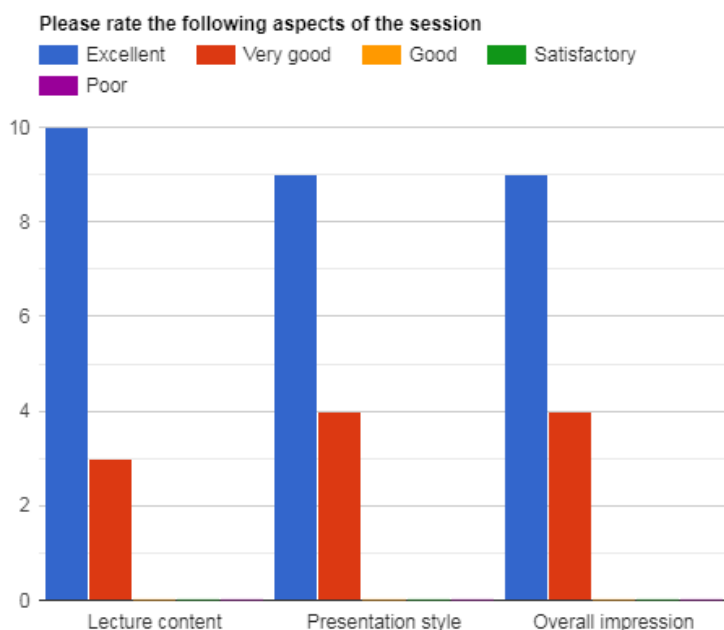
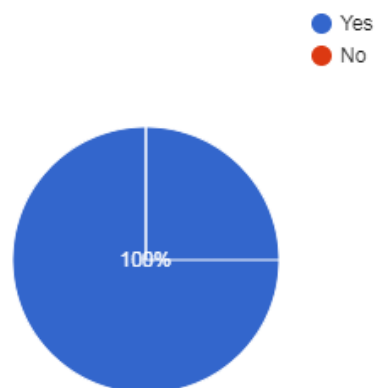


Did you find it useful
57 responses

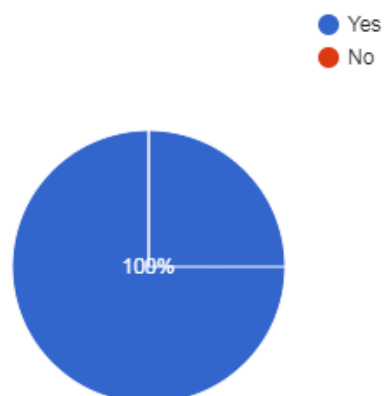




Did you find it useful
54 responses



Did you find it useful
13 responses



Testimonials

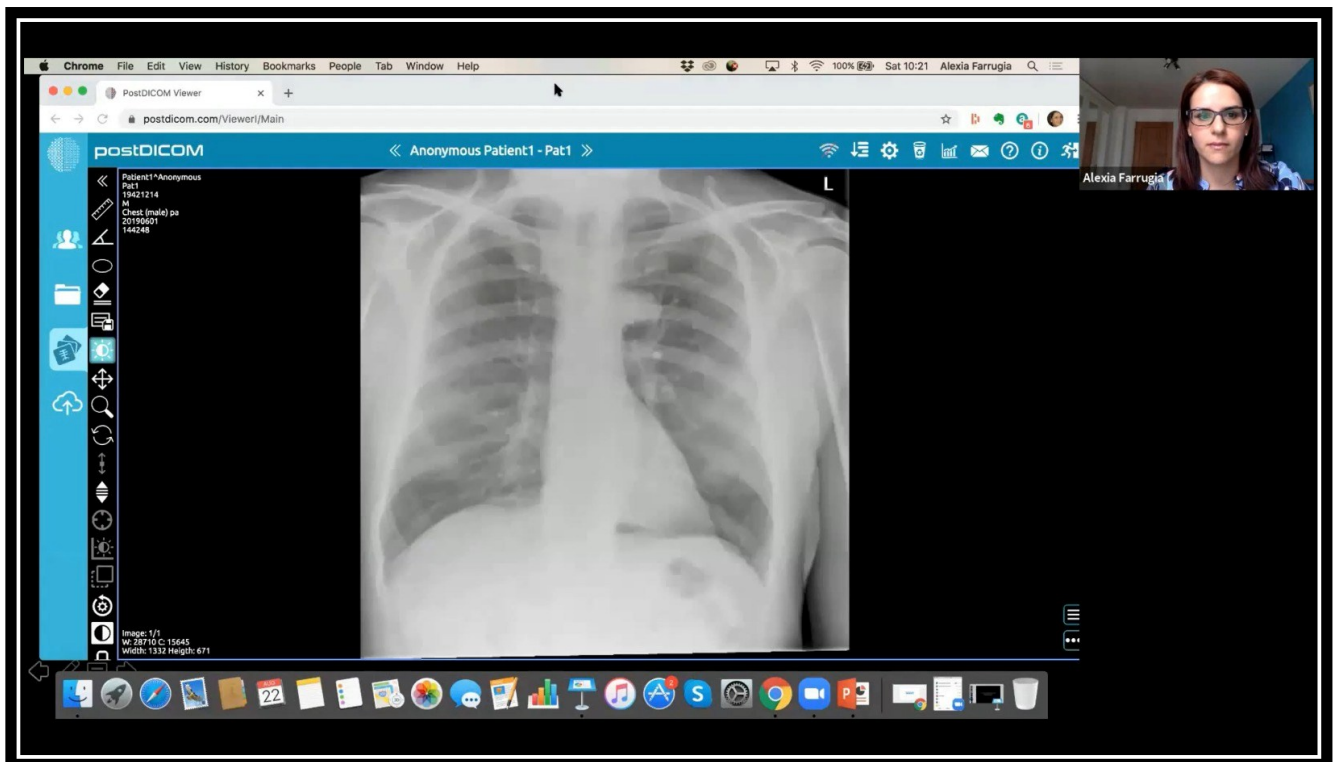
- Great presentation style. Liked the take home points in the slides and the annotations. The cases were great and very needed topics to go over. Very good teacher (UK).
- The way she explained was most valuable (India).
- Fantastic cases and great explanations with brilliant teacher (UK).
- Excellent teaching and great work to our radiology community (India).
- Lecture is excellent and contents are very useful and good exam oriented session (India).
- The time management with comprehensive explanation was outstanding. Showed so many cases in a relatively short span of time (Pakistan).

Chest & Cardiac Imaging For FRCR - Part 1

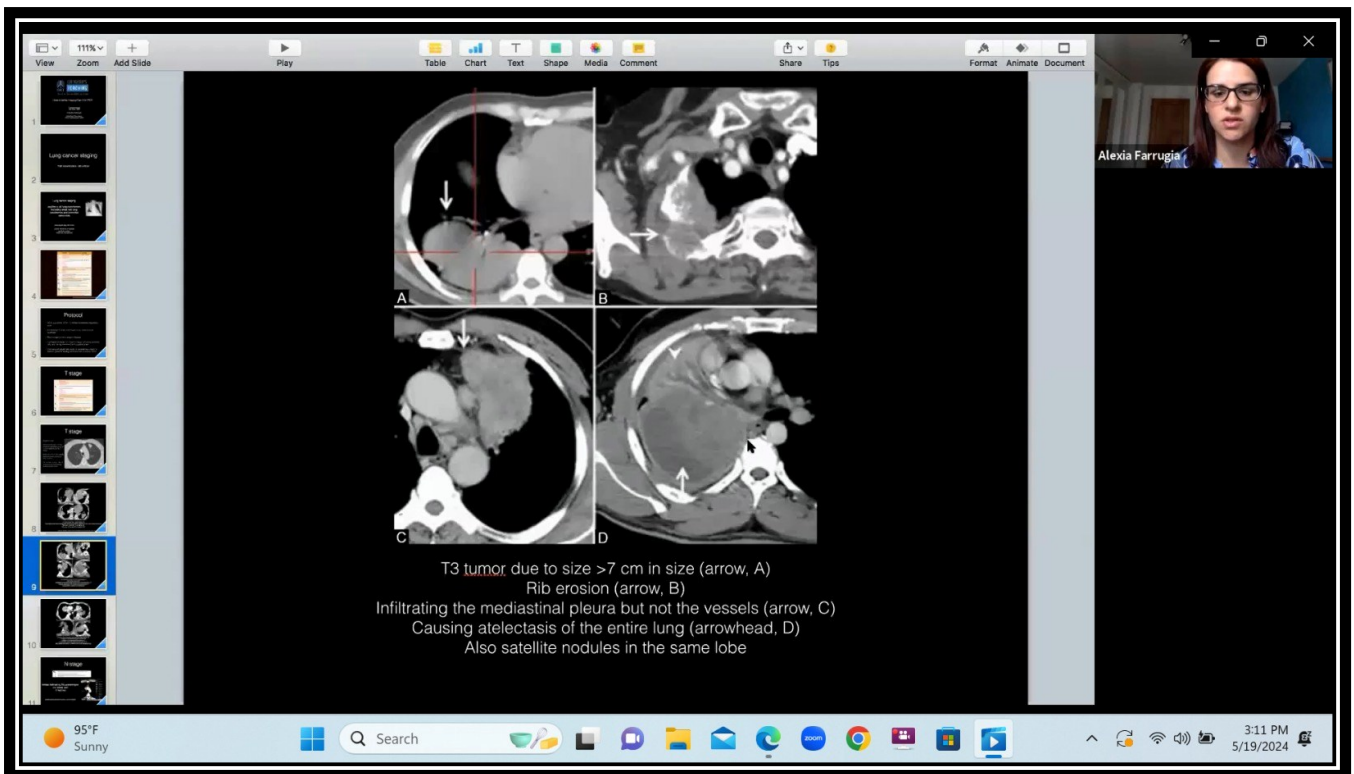
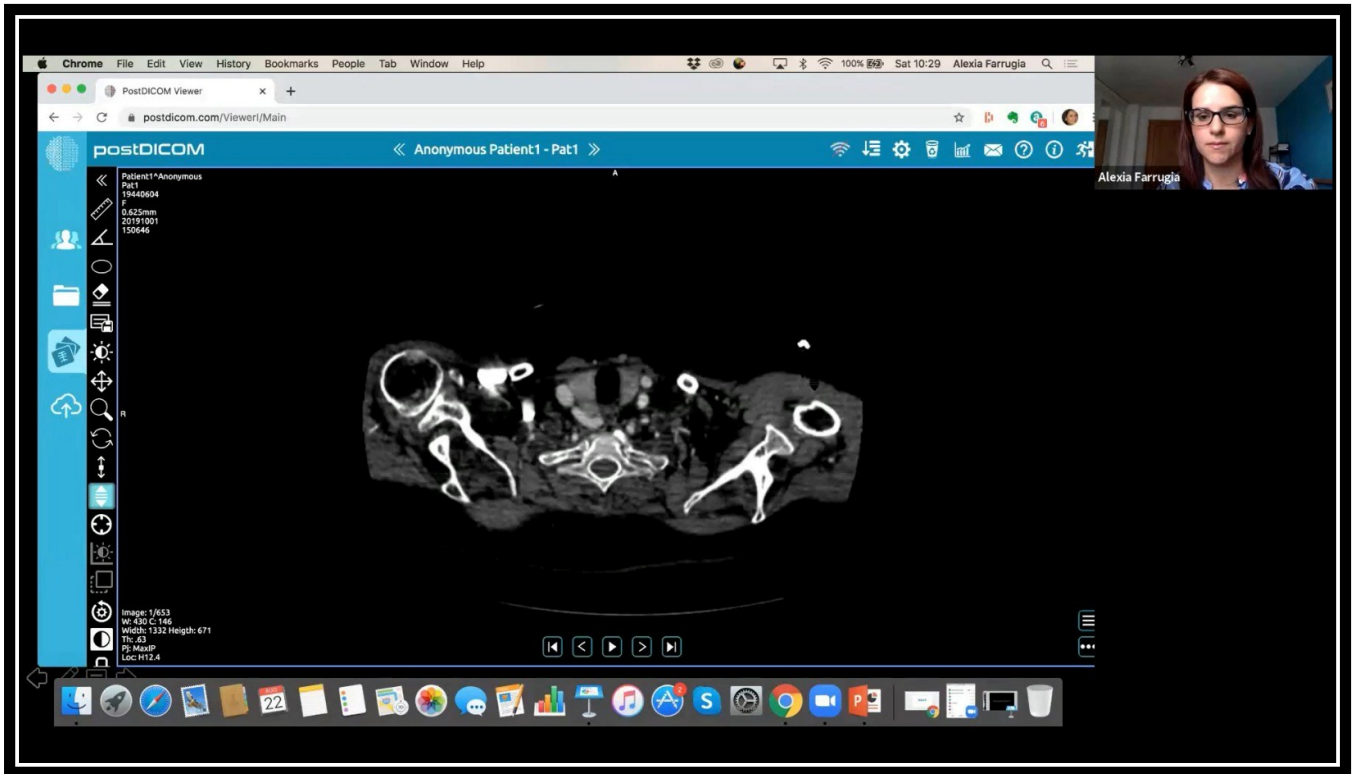
- The power point presentations with notes on the discussed conditions were most useful (Zimbabwe).
- Explanatory notes were most useful (UK).
- Interesting cases (Algeria).
- Slides and presentation style was most useful (UK)
- Cases, interpretation and discussion was most useful (India).
- Very good cases for revision (India).
- The cases are most useful (Pakistan).
- Content and delivery was most useful (UK).
- Contents are very good and excellent exam oriented lecture (India).
- Different cases were discussed. Good approach (India).
- Discussed a nice variety of pathologies in the chest (UK).
- The clinical histories given prior to the images and the case discussion PowerPoint slides were most useful (Saudi Arabia).
- Brilliant (Iraq).
- Very good coverage of different pathologies (UK).
- Excellent teaching! (UK).
- Real scenario cases (Pakistan).
- Excellent teaching (Sri Lanka).
- Case description was most useful (Nigeria).
- Excellent teaching session (Malaysia).
- Good cases for exams (UK).
- It was perfect (UAE).
- Great teaching (Pakistan).
- Very good (Egypt).
- Very informative and helpful (UAE).
- Highly impressive (UK).
- Excellent (India).
- Good teaching (UK).
- Excellent teaching session (Malaysia).
- Great (Yemen).
- Whole lecture was useful (Saudi Arabia).
- Chest pathology was most useful (Pakistan).
- Excellent cases (UK).
- The 2B exam style cases were most useful (UK).
- Great cases, very good explanation (UK).
- Every aspect was useful (India).
- Very informative and helpful (UAE).
- Very nice (India).
- Great lectures (UK).
- Absolutely impressive (Nigeria).
- Woow (Egypt).
- Outstanding (Saudi Arabia).
- Excellent session (India).
- Great! (Malaysia).
- Excellent (UK).
- Excellent (South Africa).

Chest & Cardiac Imaging For FRCR - Part 1

- Excellent (Indonesia).
- Nice cases shown (Pakistan).
- Case varieties were most useful (Malaysia).
- Live case presentation was most useful (Nigeria).
- Acute aortic syndrome-Dissection and interstitial lung disease section was most useful (UK).
- Variety of cases and modalities were most useful (Egypt).
- Content and delivery was most useful (UK).
- Nice slides to summarize whole case was most useful (Pakistan).
- Visa and teaching slides were most useful (Zimbabwe).
- LIP association with Sjogren's syndrome, constrictive pericarditis and pseudo coarctation of aorta were most useful (Zimbabwe).
- Everything was very useful (Malaysia).
- Teaching and cases were most useful (UK).
- Cases and feedback slides combination was superb (South Africa).
- Very good cases with detailed description (Pakistan).
- Images and cases tips to answer (Pakistan).
- Excellent chest and cardiovascular pathologies (Saudi Arabia).
- Nice effort in explaining different variety of cases in a very smooth way (Pakistan).



Chest & Cardiac Imaging For FRCR - Part 1



=====~~XX~~=====~~XX~~=====